State of the Art

Idiopathic Pulmonary Fibrosis
Clinical Relevance of Pathologic Classification

ANNA-LUISE A. KATZENSTEIN and JEFFREY L. MYERS

Departments of Pathology, Crouse Hospital and State University of New York Health Science Center, Syracuse, New York; and Department of Pathology and Laboratory Medicine, Mayo Clinic, Rochester, Minnesota

CONTENTS

Background
Pathologic Classification of Idiopathic Pulmonary Fibrosis
UIP
DIP/Respiratory Bronchiolitis Interstitial Lung Disease (RBILD)
AIP
NSIP
Clinical Features of the Idiopathic Interstitial Pneumonias
UIP
DIP/RBILD
AIP
NSIP
Grading of "Cellularity" and Fibrosis
Relationship of UIP and DIP
Relationship of AIP and UIP
Significance of NSIP—A Specific Disease or a Histologic Manifestation of Many Diseases?
Summary and Conclusions

Idiopathic pulmonary fibrosis (IPF), also referred to as cryptogenic fibrosing alveolitis, is a progressive interstitial lung disease of unknown etiology (1, 2, 3). Although the pathologic features of inflammation and fibrosis are widely appreciated, other diagnostically relevant findings are generally poorly understood. There is a belief in some circles, in fact, that the pathologic features of IPF are nonspecific, and that the diagnosis is made only by excluding other histologically specific entities (4). The clinical features of IPF are variable. Although the disease occurs most often in middle-aged adults, there is a wide age range, with cases reported even in young children and infants. In most patients the presentation is insidious, with a progressive course spanning several years, but cases with acute onset and fulminant course have also been described. A favorable response to corticosteroid or cytotoxic therapy occurs in one-third or less of patients. To date there has been no satisfactory explanation for the differences in age at onset, presentation, clinical course, and response to therapy of some patients with IPF. This review provides evidence that four distinct forms of interstitial pneumonia are included in the category of IPF. Failure to recognize these different entities may explain the clinical diversity observed among patients with this condition. This pathologic classification of IPF should also aid in assessing prognosis in and choosing therapy for IPF, as well as in enhancing our understanding of its pathogenesis.

(*Received in original form July 9, 1997 and in revised form October 16, 1997*)

Correspondence and requests for reprints should be addressed to A. Katzenstein, M.D., Department of Pathology, Crouse Hospital, 736 Irving Avenue, Syracuse, NY 13210.

Am J Respir Crit Care Med Vol 157. pp 1301–1315, 1998

BACKGROUND

Although Hamman and Rich described the pathologic features of four patients with unexplained interstitial pneumonia in 1944 (5), it was not until the 1960s that the interstitial pneumonias began to be studied in depth. Renewed interest at that time was fueled in part by the increased availability of lung biopsy specimens. Liebow (6) was the first to critically examine the pathologic features of the interstitial pneumonias, dividing them into five groups based on specific histologic criteria (Table 1). Other investigators, including Scadding and Hinson (7), Stack and colleagues (8), DeRemee and associates (9), Crystal and associates (10), Winterbauer and coworkers (11), and Turner–Warwick and colleagues (12), were also studying these diseases, and lumped them into a single entity using a variety of terms, including diffuse interstitial fibrosis, diffuse fibrosing alveolitis, cryptogenic fibrosing alveolitis, classical interstitial pneumonitis-fibrosis, diffuse interstitial pneumonitis and IPF. In recent years, the terms IPF and cryptogenic fibrosing alveolitis have become the accepted nomenclature.

Other than Liebow and his students, few investigators have espoused the pathologic classification of the interstitial pneumonias. In fact, some individuals have been highly critical, referring to "cryptic designations" of "UIP, DIP, and all that" (13), and likening persons using "outmoded, imprecise and ambiguous labels" to an "Australian aborigine who wanted a new boomerang but never found out how to throw the old one away" (14). Despite the criticisms, however, many of Liebow's original concepts have proven correct. For example, bronchiolitis obliterans with interstitial pneumonia (BIP), now known as bronchiolitis obliterans-organizing pneumonia (BOOP), has become a well accepted and even common diagnosis. Lymphoid interstitial pneumonia (LIP), once rare, has assumed new significance because of its association with acquired immune deficiency syndrome (AIDS), and giant-cell interstitial pneumonia (GIP) has been shown to represent the pathologic manifestation of hard-metal peumoconiosis (15). The separation of usual interstitial pneumonia (UIP) and desquamative interstitial pneumonia (DIP) has never gained wide acceptance, however, and DIP is still considered by many to represent an early or "cellular stage" of UIP (2).

PATHOLOGIC CLASSIFICATION OF IDIOPATHIC PULMONARY FIBROSIS

Four histologically distinct forms of idiopathic interstitial pneumonia comprise the morphologic spectrum that has been traditionally included under the designation of IPF, and are listed in Table 2. This classification scheme maintains UIP and DIP from Liebow's original classification and includes two additional entities, acute interstitial pneumonia (AIP or Hamman–Rich disease) (16, 17) and the recently described nonspe-

TABLE 1

LIEBOW (6) CLASSIFICATION OF INTERSTITIAL PNEUMONIA

Usual interstitial pneumonia (UIP)
Desquamative interstitial pneumonia (DIP)
Bronchiolitis obliterans with interstitial pneumonia (BIP)
Lymphoid interstitial pneumonia (LIP)
Giant cell interstitial pneumonia (GIP)

TABLE 2

PATHOLOGIC CLASSIFICATION OF IDIOPATHIC PULMONARY FIBROSIS

Usual interstitial pneumonia (UIP)
Desquamative interstitial pneumonia (DIP)/respiratory bronchiolitis interstitial lung disease (RBILD)
Acute interstitial pneumonia (AIP, Hamman–Rich disease)
Nonspecific interstitial pneumonia (NSIP)

cific interstitial pneumonia (NSIP) (18). Lymphoid interstitial pneumonia and GIP, although remaining important forms of interstitial pneumonia in general, are not included in the category of IPF because they are usually not idiopathic; LIP is a lymphoproliferative disorder often associated with immunodeficiencies, and GIP is usually a manifestation of hard-metal pneumoconiosis. BIP, or BOOP, is also not included in this classification since, pathologically, it is a predominantly intraluminal rather than interstitial abnormality. Also, radiographically, its most common manifestation is characterized by patchy air space opacities rather than diffuse interstitial shadows.

That these pathologic subcategories comprising IPF have not been widely espoused can be explained by the fact that IPF is often diagnosed on the basis of clinical assessment, without the benefit of an open-lung biopsy. Even when biopsy specimens are available, consistent pathologic criteria for diagnosis have not been applied. Table 3 lists the diagnostic criteria used in 11 major (20 or more cases) series of IPF cases since 1972. Open-lung biopsies were examined in only a minority (38%) of the more than 1,000 cases reported. In only two series (9, 10), containing 29 and 96 patients, respectively, were open-lung biopsies consistently examined. The pathologic criteria for diagnosis used by most investigators included only the presence of fibrosis and inflammation in varying proportions, a finding shared by all the idiopathic interstitial pneumonias. Important differences in the distribution, intensity, and nature of the fibrosis and inflammation, however, were generally not appreciated, and these differences form the basis for the pathologic classification of these entities. Thus, with few exceptions, even those series containing biopsy-proven cases failed to recognize the pathologic variants of IPF. Although Cherniack and associates (9) carefully examined multiple pathologic features in their 96 cases, all were diagnosed as UIP. The lack of DIP cases among such a large number of interstitial pneumonias would be very unusual. Moreover, the fact that severe and extensive interstitial inflammation was documented in some cases suggests that examples of NSIP may have been included.

Our classification scheme for IPF is easily and consistently reproducible, and has important clinical implications. The major pathologic and clinical features of the four idiopathic interstitial pneumonias are contrasted in Tables 4 and 5, and detailed pathologic and clinical descriptions of each are provided in the following sections. It should be remembered that diagnosing these entities requires a wedge of lung that can only be supplied by thoracoscopy or thoracotomy, and that small biopsy specimens such as percutaneous needle and transbronchial biopsies cannot provide sufficient tissue.

UIP

The presence of a patchy, nonuniform, and variable distribution of interstitial changes is an important diagnostic clue to

TABLE 3

CRITERIA UTILIZED FOR DIAGNOSING IPF IN MAJOR SERIES

Author, Year	No. of Cases	Criteria for Diagnosing IPF	Comment
Stack and colleagues (8), 1972	96	Clinical with biopsy or autopsy in some (48 of 96, including 24 OLB and 6 drill)	OLB in only 24 of 96 (25%)
DeRemee and colleagues (19), 1972	81	CXR and TBB (81 of 81)	TBB only, no OLB
Crystal and colleagues (10), 1976	29	Clinical and histologic (OLB in 29 of 29)	OLB in all
Turner–Warwick and colleagues (12), 1980	220	Clinical and biopsy in some (66 of 220 including 50 OLB, 16 drill/needle); autopsy in 52	OLB in only 50 of 220 (23%)
Tukiainen and colleagues (20), 1983	100	Clinical and biopsy in some (64 of 100 including 50 needle, 1 TBB, 13 OLB); autopsy in 6	OLB in only 13 of 100 (13%)
Agusti and colleagues (21), 1992	20	Clinical with biopsy in some (OLB 4 of 20)	OLB in only 4 of 20 (20%)
Baughman and colleagues (22), 1992	33	Clinical, biopsy also in most (32 of 33 including 30 TBB, 2 OLB); autopsy in 1	OLB in only 2 of 33 (6%)
Schwartz and colleagues (23), 1994	74	Clinical with biopsy in most (67 of 74, including 49 OLB, 18 TBB)	OLB in only 49 of 74 (66%)
Wells and colleagues (24), 1994	273	Clinical and/or histologic criteria (OLB in 147 of 273)	OLB in only 147 of 273 (54%)
Cherniack and colleagues (9), 1995	96	Biopsy (96 of 96 OLB)	All OLB. 96 of 96 UIP, no DIP identified
Hanson and colleagues (25), 1995	58	Clinical and biopsy (TBB or OLB, number not specified)	No. of OLB not stated
Total cases*	1,022		OLB in 385 of 1,022 (38%)

Definition of abbreviations: OLB = open lung biopsy; TBB = transbronchial lung biopsy.
* Excluding Hanson and colleagues' (25) study, since the number of OLB was not stated.

TABLE 4

CONTRASTING PATHOLOGIC FEATURES OF THE IDIOPATHIC INTERSTITIAL PNEUMONIAS

Features	UIP	DIP/RBILD	AIP	NSIP
Temporal appearance	Variegated	Uniform	Uniform	Uniform
Interstitial inflammation	Scant	Scant	Scant	Usually prominent
Collagen fibrosis	Yes, patchy	Variable, diffuse (DIP) or focal, mild (RBILD)	No	Variable, diffuse
Fibroblast proliferation	Fibroblast foci prominent	No	Diffuse	Occasional, diffuse, or rare fibroblast foci
BOOP	No	No	No	Occasional, focal
Microscopic honeycomb change	Yes	No	No	Rare
Intraalveolar macrophage accumulation	Occasional, focal	Yes, diffuse (DIP) or peribronchiolar (RBILD)	No	Occasional, patchy
Hyaline membranes	No	No	Occasional, focal	No

Definition of abbreviations: AIP = acute interstitial pneumonia; DIP/RBILD = desquamative interstitial pneumonia/respiratory bronchiolitis interstitial lung disease; NSIP = nonspecific interstitial pneumonia; UIP = usual interstitial pneumonia; BOOP = bronchiolitis obliterans organizing pneumonia.

UIP, and this appearance is readily appreciated at low magnification (Figure 1). Histologic variation from one low-magnification field to another is characteristic, with alternating zones of interstitial fibrosis, inflammation, honeycomb change, and normal lung. Most of the fibrosis consists of eosinophilic collagen with few associated inflammatory or stromal cells. This collagen deposition thickens alveolar septa and forms patchy scars. It also accompanies areas of honeycomb change. The latter are characterized by enlarged air spaces lined by bronchiolar epithelium or hyperplastic alveolar pneumocytes, and separated by thick walls containing collagen and varying amounts of chronic inflammation. The enlarged air spaces may be empty, but frequently contain inspissated mucin admixed with histiocytes, neutrophils, and other inflammatory cells. Honeycomb change is a manifestation of scarring and architectural restructuring that follows lung injury of a variety of causes, and it is not specific to UIP. The pathogenesis appears to be related in part to alveolar collapse and reorganization (26). It is considered an irreversible change and is sometimes referred to as "end-stage lung."

Another facet of the histologic variability of UIP is appreciated when the nature of the fibrosis is examined. Although most of the fibrotic zones are composed of "old," relatively acellular collagen bundles, small aggregates of actively proliferating myofibroblasts and fibroblasts are consistently identifiable (27–29). These aggregates, termed "fibroblast foci," are characterized by spindle-shaped cells present within lightly staining, myxoid-appearing matrix, and which are usually arranged with their long axis parallel to the long axis of the alveolar septa (Figure 2). They are easily visualized even at low magnification because their light-staining matrix contrasts with the more darkly staining adjacent lung parenchyma. Fibroblast foci are widely scattered and can be found in inflamed, fibrotic, and honeycomb areas. Electron microscopic studies have shown that these foci represent the organization of prior foci of acute lung injury (27, 35, 36), and active collagen synthesis by the component myofibroblasts has been demonstrated by immunohistochemistry (29). The evolution of the fibroblast foci has been likened to the sequence of events characteristic of wound healing in skin and other tissues (29). The presence of the proteoglycans versican and decoran, as well as of other substances such as integrin, vinculin, and tenescin, has been demonstrated in fibroblast foci by immunohistochemistry (27, 37, 38). Although fibroblast foci are not pathognomonic for UIP, they are necessary for the diagnosis. They indicate that the fibrosis is actively ongoing rather than representing the residuum of a process that occurred in the past but is now inactive. The presence of fibroblast foci in some places, and of scarring with collagen deposition or honeycomb change in others, comprises the essence of temporal heterogeneity, a feature that is central to diagnosing UIP and distinguishing it from other idiopathic interstitial pneumonias.

Inflammation, usually of mild degree and composed mainly of small lymphocytes, accompanies the other interstitial changes in UIP. Scattered plasma cells as well as occasional neutrophils and eosinophils may also be present, but generally are not numerous. The inflammation occurs mainly in areas of collagen deposition or honeycomb change, and rarely in oth-

TABLE 5

CONTRASTING CLINICAL FEATURES OF THE IDIOPATHIC INTERSTITIAL PNEUMONIAS

Features	UIP	DIP	RBILD	AIP	NSIP
Mean age, yr	57	42	36	49	49
Occurrence in children	No	Rare	No	Rare	Occasionally
Onset	Insidious	Insidious	Insidious	Acute	Subacute, insidious
Mortality rate (mean survival)	68% (5–6 yr) (ref. 24, 28, 30, 31)	27% (12 yr) (ref. 30)	0% (ref. 32, 33)	62% (1–2 mo) (ref. 16, 17, 34)	11% (17 mo) (ref. 18)
Response to steroids	Poor	Good	Good	Poor	Good
Complete recovery possible	No	Yes	Yes	Yes	Yes

Definition of abbreviations: AIP = acute interstitial pneumonia; DIP = desquamative interstitial pneumonia; NSIP = nonspecific interstitial pneumonia; RBILD = respiratory bronchiolitis interstitial lung disease; UIP = usual interstitial pneumonia.

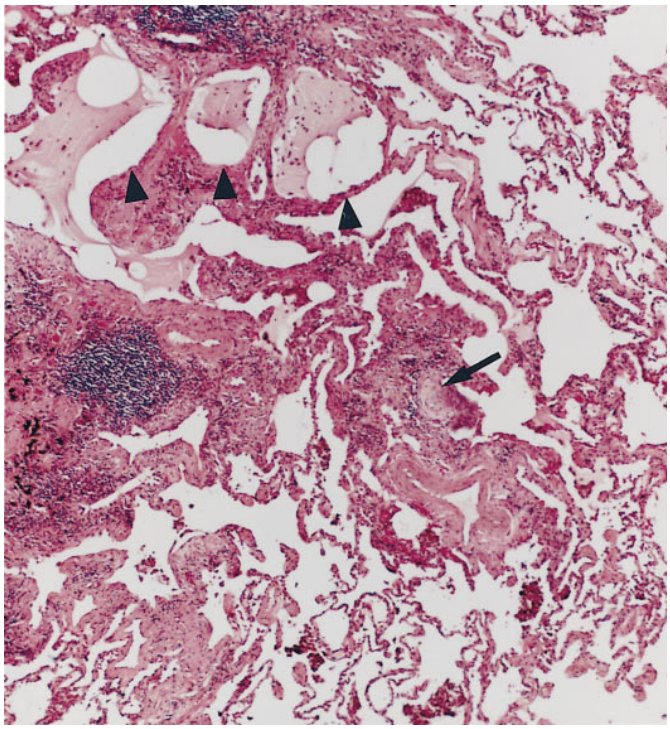

Figure 1. Low magnification view of UIP, showing the characteristic marked variation in histologic appearance from one area to another. Interstitial fibrosis with dense collagen deposition is seen on the left, and patchy areas containing normal alveolar septa are present nearby (*right* and *bottom center*). There is a zone of microscopic honeycomb change at the top left (*arrowheads*) that is characterized by mucin-filled, enlarged air spaces separated by fibrosis. A fibroblast focus (*arrow*) is seen in an area of fibrosis and inflammation in the center of the field. Hematoxylin and eosin; original magnification: ×48.

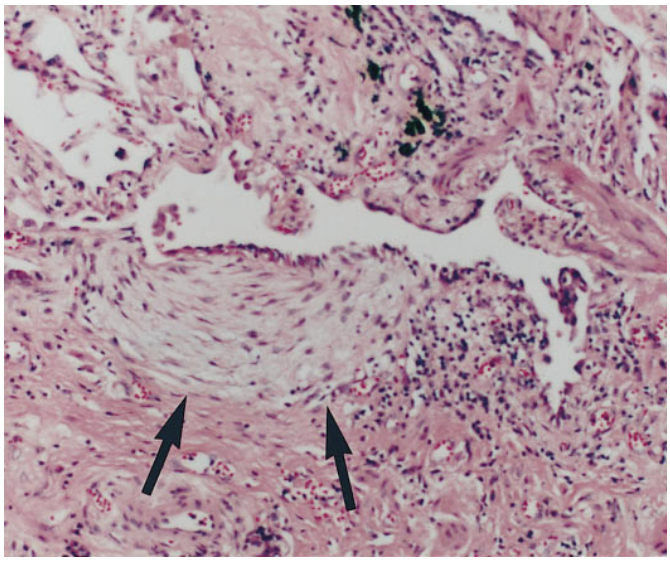

Figure 2. Fibroblast focus in UIP (*arrows*). The characteristic aggregate of spindle-shaped cells arranged in parallel beneath hyperplastic alveolar lining cells is easily visible because the light-staining matrix contrasts with the more darkly staining adjacent parenchyma. Fibroblast foci represent areas of active fibrosis that contrast with adjacent areas of inactive collagen-type fibrosis. Hematoxylin and eosin; original magnification: ×300.

erwise unaltered alveolar septa. There is no evidence that inflammation is more prominent in early disease. The presence of severe inflammation, in fact, should suggest a diagnosis other than UIP.

Intraalveolar macrophage accumulation is a common nonspecific finding in UIP, and it also bears no relationship to stage of disease. Its presence, however, has caused considerable confusion and controversy both about the existence of DIP as a separate entity and about the relationship of UIP and DIP. Once the other diagnostic features of UIP, especially the nonuniform distribution of changes and the temporal heterogeneity, are recognized, however, the distinction of UIP from DIP (*see the subsequent discussion*) is not difficult, even in cases with prominent intraalveolar macrophage accumulation.

DIP/Respiratory Bronchiolitis Interstitial Lung Disease

The most striking histologic finding in DIP is the presence of increased numbers of macrophages evenly dispersed within alveolar spaces (Figure 3) (39–41). These cells have abundant cytoplasm that often contains finely granular, yellow-brown pigment derived from complex phagolysosomes (Figure 4). Most are mononuclear, although scattered multinucleated giant cells may be observed. These cells were originally thought to represent epithelial cells exfoliated or "desquamated" from the alveolar septa, and thus the name DIP is a misnomer. Minimal to moderate alveolar septal widening usually accompanies the air space changes and is generally characterized by collagen deposition with a scant inflammatory-cell infiltrate. Hyperplastic alveolar epithelial lining cells are visible at least focally, and they may be numerous. Fibroblast foci are not a feature, however, and honeycomb change is minimal if present at all. The overall appearance at low magnification is one of monotonous uniformity from one field to another which contrasts sharply with the prominent heterogeneity of histologic changes in UIP.

The macrophage accumulation in DIP is often accentuated within peribronchiolar air spaces, but when the macrophage accumulation is confined to these areas with sparing of more distal air spaces, the process is termed respiratory bronchiolitis interstitial lung disease (RBILD) (32, 33). This term is derived from respiratory bronchiolitis, also known as smokers' bronchiolitis, a common incidental finding in cigarette smokers. It is characterized by the accumulation of pigmented macrophages within respiratory bronchioles, without significant accompanying interstitial lung disease (42). In RBILD, interstitial thickening similar to that seen in DIP accompanies the air space changes but is confined to the peribronchiolar parenchyma. Although initial reports considered RBILD to be distinct from DIP (32), it seems more likely that these two entities represent different ends of a spectrum of the same disease. This conclusion is based on the lack of a sharp histologic distinction between the two lesions, as well as a similar presentation and course. That 90% of Carrington and colleagues' (30) DIP patients and all reported patients with RBILD were cigarette smokers suggests a common pathogenesis related to cigarette smoking.

RBILD may be a better term than DIP because it is anatomically correct, and also because it emphasizes the putative role of cigarette smoking or other environmental exposures in the pathogenesis of this condition. Consideration should be given, therefore, to discarding DIP altogether and replacing it by RBILD.

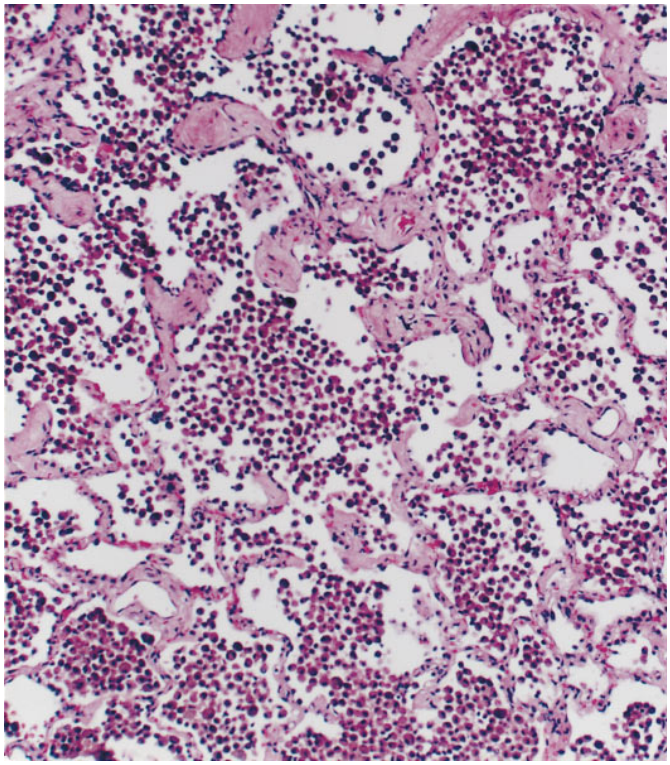

Figure 3. Low magnification view of DIP showing the characteristic filling of alveolar spaces by macrophages, accompanied by mild to moderate thickening of alveolar septa. Note the uniformity of the changes from one area to another. Hematoxylin and eosin; original magnification: ×120.

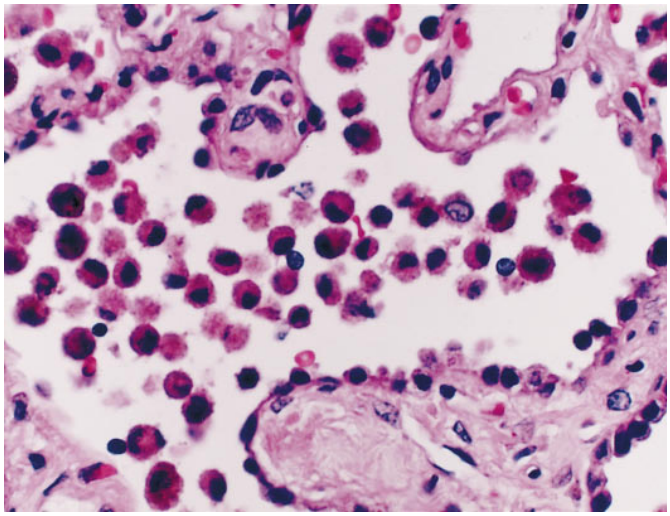

Figure 4. Higher magnification view of DIP, showing the evenly dispersed macrophages within an alveolar space. The cells contain an eccentric nucleus and abundant, lightly pigmented cytoplasm. The alveolar septa are moderately thickened by collagen deposition, and there is prominent alveolar pneumocyte hyperplasia. Hematoxylin and eosin; original magnification: ×480.

AIP

AIP is characterized by diffuse interstitial fibrosis, but it differs from the other interstitial pneumonias in that the fibrosis is active, consisting of proliferating fibroblasts and myofibroblasts with minimal collagen deposition (Figure 5) (16, 17). The changes are therefore temporally uniform and appear relatively acute, reflecting the reaction to lung injury occurring several weeks previously. They resemble the organizing stage of diffuse alveolar damage (DAD), a well-documented sequence of pathologic changes that has been described after a wide variety of noxious lung insults (15). The characteristic fibroblast proliferation occurs within a myxomatous-appearing stromal background within thickened alveolar septa (Figure 6). The appearance is identical to that of the fibroblast foci in UIP except that the process is diffuse rather than focal. Epithelial necrosis and alveolar collapse resembling that occurring in the fibroblast foci of UIP are present diffusely in AIP, and a similar deposition of proteoglycans is seen immunohistochemically in both diseases (26, 36, 37). If the process continues for a sufficient period, usually more than a month, enlarged, restructured air spaces can be formed, and the appearance resembles the honeycomb change in UIP. It differs from the latter, however, in that the walls of the air spaces are composed of fibroblasts as well as collagen, and are lined by alveolar rather than bronchiolar epithelium. This rapid development of honeycomb change results from partial or complete collapse of some alveoli with subsequent enlargement of others (26). Ventilator therapy with high pressures probably also plays a role in this change (43).

Other manifestations of acute lung injury are frequent accompanying features in AIP. They include remnants of hyaline membranes within alveolar spaces, small arterial thrombi, and squamous metaplasia with cytologic atypia in bronchiolar epithelium.

NSIP

NSIP is characterized by the presence of varying degrees of inflammation and fibrosis within alveolar walls, but it lacks

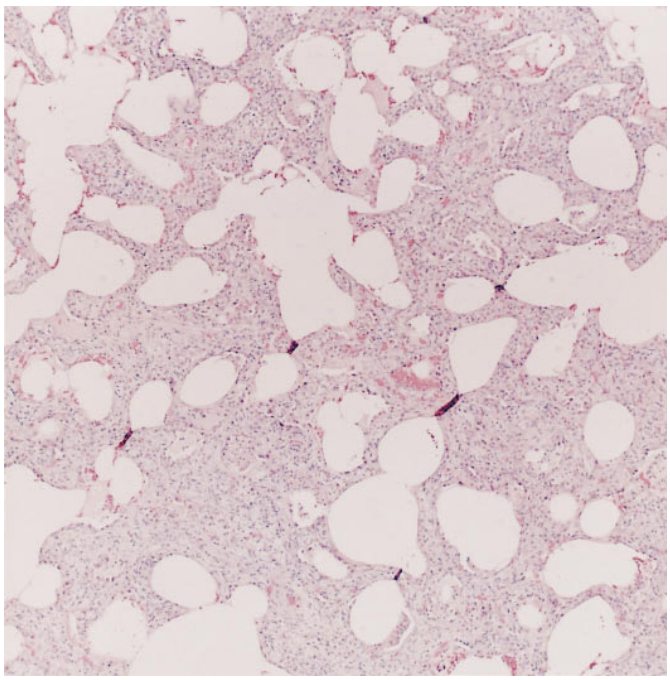

Figure 5. Photomicrograph of AIP, showing the characteristic, temporally uniform thickening of alveolar septa by a mixture of mononuclear cells. Although the size of the air spaces and the degree of interstitial thickening vary from one area to another, the component cellular infiltrate remains constant. Hematoxylin and eosin; original magnification: ×120.

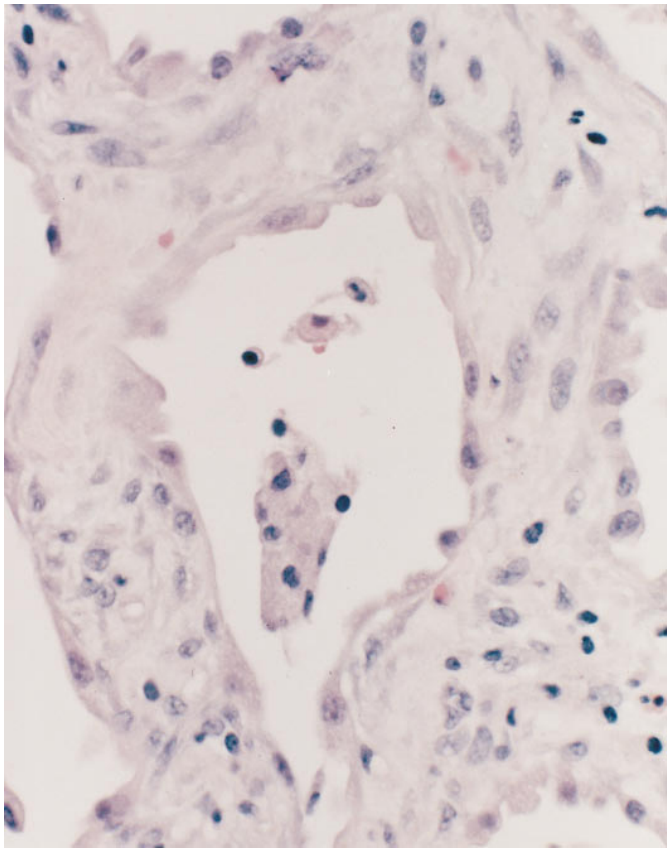

Figure 6. Higher-magnification view of an alveolus in AIP, showing that most of the alveolar septal thickening is due to the presence of oval to spindle-shaped fibroblasts and a few scattered small lymphocytes. Alveolar pneumocyte hyperplasia along the alveolar walls is prominent as well. Hematoxylin and eosin; original magnification: ×480.

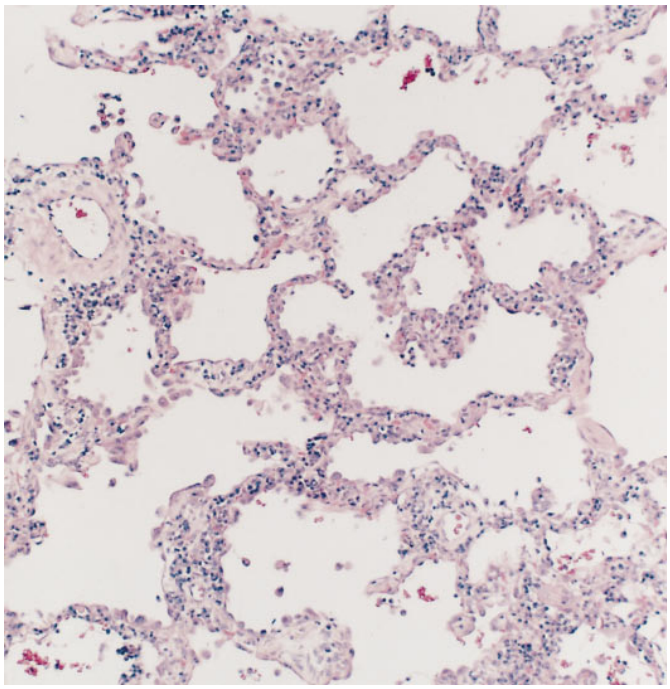

Figure 7. Low-magnification photomicrograph of NSIP, showing diffuse, uniform thickening of alveolar septa. Even at this low magnification the cellular nature of the interstitial infiltrate can be appreciated. Hematoxylin and eosin; original magnification: ×120.

more specific changes that would indicate a diagnosis of UIP, DIP, or AIP (18). Most examples contain either inflammation with minimal fibrosis or a mixture of inflammation and fibrosis, although a few are composed mainly of fibrosis with minimal inflammation. The process may be patchy with intervening areas of unaffected lung, but the changes are temporally uniform in that they appear to have occurred over a single, relatively narrow time span. This temporal uniformity contrasts sharply with the temporal heterogeneity characteristic of UIP.

Examples of NSIP composed predominantly of interstitial inflammation with little or no fibrosis constitute nearly half the reported cases, and are the easiest to recognize histologically (Figure 7). A chronic inflammatory-cell infiltrate containing a mixture of lymphocytes and plasma cells within alveolar septa is characteristic of NSIP, and plasma cells are often numerous (Figure 8). The process is frequently accentuated in the peribronchiolar interstitium. Alveolar pneumocyte hyperplasia often accompanies the interstitial inflammation and may be prominent. The density of the inflammatory infiltrate characteristic of this form of NSIP is considerably greater than that occurring in any of the other idiopathic interstitial pneumonias. Although LIP may enter the differential diagnosis, the marked architectural distortion by the cellular infiltrate typical of this entity is not present. Also, plasma cells are usually more prominent in NSIP than in LIP.

In approximately 40% of cases of NSIP there is an equal mixture of inflammation and fibrosis characterized by intermingling collagen bundles, lymphocytes, plasma cells, and occasionally fibroblasts (Figure 9). These cases can sometimes be difficult to distinguish from UIP. The clue to diagnosis is that the changes appear relatively uniform from field to field, and significant architectural remodeling (honeycomb change)

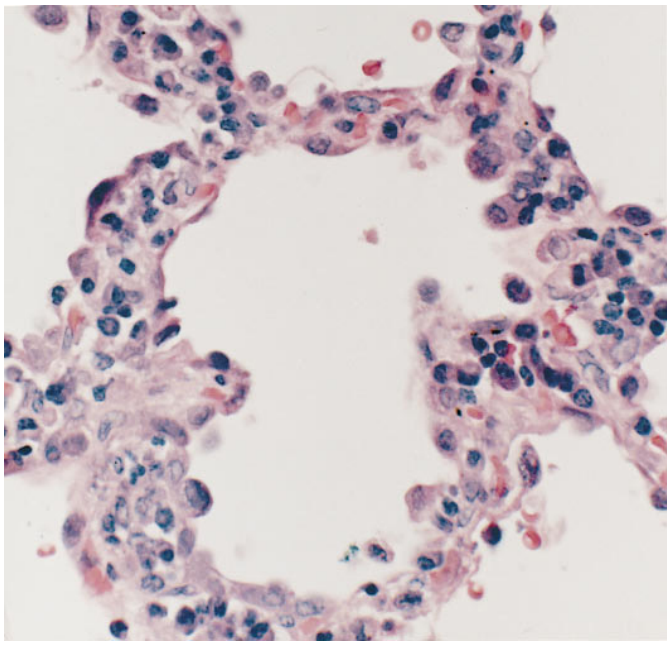

Figure 8. Higher-magnification view of alveoli in Figure 7, showing a mixture of small lymphocytes and plasma cells thickening the alveolar septa in this example of NSIP. Hematoxylin and eosin; original magnification: ×300.

is not present. Fibroblast foci may occur in a few cases, but are never numerous.

Interstitial collagen deposition with minimal inflammation is present in about 10% of cases of NSIP. The process appears inactive and probably represents areas of old scarring. It may be patchy or diffuse. Although the presence of extensive fibrosis may initially suggest UIP, the uniformity of the changes and the lack of active fibrosis easily distinguish NSIP from this entity.

Other features commonly accompany the interstitial inflammation and fibrosis in NSIP. Foci of intraluminal organization characteristic of BOOP are seen in nearly half of cases. These foci are always small and inconspicuous, however, and by definition constitute less than 10% of the overall changes. Patchy intraalveolar macrophage accumulation occurs in 30% of cases, and the macrophages may be admixed with variable numbers of lymphoid cells. This finding is easily distinguished from DIP because of its patchy distribution and the prominent associated interstitial changes. Lymphoid aggregates with germinal centers (so-called lymphoid hyperplasia) are present in approximately one fourth of cases of NSIP, although the lymphoid aggregates are usually widely scattered and never numerous. Rarely, poorly formed, nonnecrotizing granulomas accompany the other changes, but they are always focal.

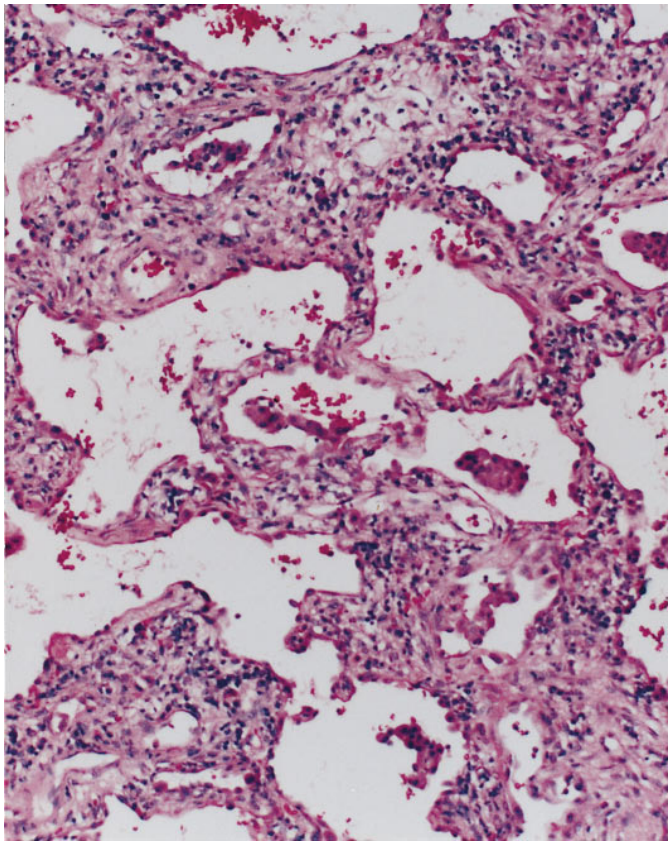

Figure 9. A mixture of collagen fibrosis and chronic inflammatory cells thickens the alveolar septa in this example of NSIP. The areas of prominent collagen deposition appear eosinophilic (*top left* and *bottom right*), and contrast with adjacent areas containing small, darkly staining round lymphoid cells. Hematoxylin and eosin; original magnification: ×120.

CLINICAL FEATURES OF THE IDIOPATHIC INTERSTITIAL PNEUMONIAS

UIP is the most common idiopathic interstitial pneumonia, accounting for over 60% of IPF cases in Bjoraker and colleagues' (44) study. NSIP is second in frequency, whereas DIP and AIP are relatively rare. For clinical purposes, the distinction of UIP from NSIP and DIP has the greatest relevance, because of marked differences in prognosis and therapy for these diseases (44). The following sections detail the clinical findings in each of the idiopathic interstitial pneumonias, and Table 5 summarizes the main contrasting features of these diseases.

UIP

It is difficult to identify well-selected, pathologically confirmed cases of UIP from which to glean clinical data. Table 6 lists the main findings in seven studies which on review were considered to contain at least a majority of well diagnosed UIP cases. The examples reported by Crystal and associates (10), Katzenstein and coworkers (28), Guerry-Force and associates (31), and Bjoraker and colleagues (44) are the best documented pathologically. The classic article by Carrington (30) is slightly flawed by the inclusion of two cases of drug toxicity (nitrofurantoin and procainamide hydrochloride) and three examples of familial UIP. Cherniack and colleagues' (9) series probably included some examples of NSIP and perhaps even of DIP. The large series reported by Wells and coworkers (24) suffers from a similar lack of critical pathologic review, but the majority of cases appear to represent UIP. Other large series of cases of IPF are not included in this analysis because adequate histologic documentation was not provided (8, 12, 19, 20).

It is clear from these studies that UIP occurs predominantly in middle-aged adults, and that men are affected nearly twice as often as women. The disease rarely if ever occurs in children. Although Carrington and associates' (30) series included a 15-year-old, this young individual may have been one of the three "familial" cases included in this study. Familial UIP is probably a different entity from UIP and should be considered separately. The most common presenting complaints include breathlessness and cough, and the onset is usually insidious. Systemic symptoms, including fever, malaise, joint symptoms, and weight loss were noted in nearly half of the patients reported by Crystal and associates (10), although fever is a generally uncommon finding, having occurred in only 15% (five of 33) of cases in which it was specifically distinguished from other systemic symptoms (28, 31). Clubbing is frequently encountered on physical examination, occurring in over half the patients in some series, and fine, crackling rales are observed on chest examination in most cases (10, 12, 31, 44). A number of laboratory abnormalities may be present, even in individuals without associated collagen-vascular diseases, including an increased erythrocyte sedimentation rate, antinuclear antibodies, cryoglobulins, and rheumatoid factor (10, 12). Chest radiographs and CT examinations show decreased lung volume, interstitial linear or reticular opacities, areas of ground-glass appearance, and varying degrees of honeycomb change (30, 31, 45). The changes are often accentuated at the lung bases. Normal chest radiographs have occasionally been reported, including four of Carrington and colleagues' (30) 53 patients and three of 147 patients described by Turner–Warwick and coworkers (12). Physiologic abnormalities are uniformly present, including moderate to severe restrictive defects and decreased diffusion capacity (10, 12, 24, 30, 31, 45).

The prognosis in UIP is poor, with mortality rates ranging from 59% to 70%. The mean duration from diagnosis to death was nearly 6 yr in Carrington and colleagues' (30) series, and

TABLE 6

CLINICAL FINDINGS IN HISTOLOGICALLY CONFIRMED CASES OF UIP OR IPF

Author, Year	No. Patients	M/F (*ratio*)	Average age (*yr; range*)	Systemic Symptoms	Outcome (*length of survival*)
Crystal and colleagues (10), 1976	29	15/14 (1.1:1)	52	48%*	Not stated
Carrington and colleagues (30), 1978	53	33/20 (1.65:1)	51 (15–72)	Not stated	36 of 53 (66%) died (mean survival 5.6 yr, range 1–17 yr)
Katzenstein and colleagues (28), 1986	16	13/3 (4.3:1)	58 (29–77)	2 of 15 (13%) (fever)	10 of 16 (63%) died (mean survival 15 mo, range: 5 mo–3.5 yr)
Guerry-Force and colleagues (31), 1987	18	10/8 (1.25:1)	55	3 of 18 (17%) (fever)	10 of 17 (59%) died
Wells and colleagues (24), 1994	108	80/28 (2.9:1)	53	Not stated	142 of 205 (70%) died†
Cherniack and colleagues (9), 1995	96	61/35 (1.7:1)	62 (28–77)	Not stated	Not stated
Bjoraker and colleagues (44), 1997	63	33/30 (1.1:1)	65 (32–72)	Not stated	Median survival 2.8 yr
Total cases	383	245/138 (1.8:1)	57 (15–77)	19 of 62 (31%)	198 of 291 (68%) died

Definition of abbreviations: IPF = idiopathic pulmonary fibrosis; UIP = usual interstitial pneumonia.
* Includes fever, fatigue, weight loss and arthralgias.
† Includes all patients (with and without biopsy confirmation).

the overall median survival reported by Bjoraker and coworkers (44) was 2.8 yr. Slightly lower mortality rates, averaging 50 to 55%, have been reported in other large series of cases of IPF lacking adequate histologic confirmation (12, 20, 23, 25, 46). This lower mortality rate may reflect dilution of UIP cases by other forms of idiopathic interstitial pneumonia in these series. Most patients are treated with steroids, and there is some evidence for additional benefit from cyclophosphamide or azathioprine (22, 47–49). Recently, colchicine has been reported to be as effective as steroids (50).

DIP/RBILD

The clinical findings in the largest reported series of cases of DIP are summarized in Table 7. The average age at onset of all cases was 45 yr, about 10 yr younger than patients with UIP, and, if the series of Tubbs and colleagues (51) and Patchefsky and associates (52) are omitted, it drops to 42 yr. The latter investigators included cases that did not completely fit with Liebow's criteria for the diagnosis of DIP, in that they lacked histologic uniformity or contained severe interstitial fibrosis. Additionally, an open-lung biopsy was done in only 17 of the 26 cases in Tubbs and colleagues' (51) study. It is therefore likely that these authors misdiagnosed at least some cases of UIP or other interstitial pneumonias as DIP.

All studies have noted a male preponderance of DIP, with men affected nearly twice as often as women. Dyspnea and cough are the most common presenting complaints, and the onset is usually insidious. Clubbing is a frequently associated finding, occurring in nearly half of patients. Laboratory studies have been generally unrewarding. Restrictive defects with a decreased diffusion capacity are commonly found on pulmonary function testing, but abnormalities are usually less marked than observed in cases of UIP. Bibasilar chest-radiographic opacities with a hazy, ground-glass appearance are present in about one fourth of patients. Although this radiographic appearance was considered a characteristic feature of DIP in early reports, subsequent studies more often showed a nonspecific linear or reticulonodular interstitial pattern. In contrast to UIP, however, honeycombing is usually not present in DIP, even on high-resolution CT scans (53, 54).

The best data regarding outcome are found in Carrington and associates' (30) large series. Eleven of their 40 patients (27.5%) died after an average survival of 12 yr. Interestingly, 22% improved without therapy, including six who recovered completely, and among treated patients, a beneficial response to steroid therapy was observed in over 60%. Yousem and coworkers (41) noted a slightly higher mortality rate (32%, or eight of 25 patients with follow-up). Most of their patients, however, were included in previous reports by Gaensler and associates (39) and Carrington and colleagues (30), and it is difficult to compare their findings. Hartman and colleagues (54) reported radiographic stabilization or improvement in most of their 11 patients with DIP as compared with progression in most of the 12 UIP patients, although details on follow-up interval and survival data are not provided. Similar radiographic stabilization or improvement was reported by Akira and coworkers (53) in sequential CT scans of eight patients after a mean follow-up of 3.2 yr.

Two studies have described patients with RBILD (32, 33). The mean age at onset was 36 yr in both studies, which was considerably less than that noted in patients with either DIP or UIP. In fact three of six individuals reported by Myers and colleagues (32) were younger than 30 yr of age. As with most other forms of interstitial pneumonia, there is a slight male predominance of RBILD. Symptoms are generally mild, with cough and dyspnea comprising the most common complaints. Clubbing was specifically noted to be absent in all of Yousem and colleagues' (33) 18 cases. All patients with RBILD are cigarette smokers. It is interesting in this regard that 90% (36 of 40) of Carrington and colleagues' (30) patients with DIP smoked cigarettes, as compared with 71% (38 of 53) of their UIP patients. Radiographically, reticular or reticulonodular infiltrates are present in over two thirds of patients with RBILD. Normal chest radiographs were found in five of 18 patients in Yousem and colleagues' (33) study, and these investigators also noted the consistent absence of ground-glass opacities. All patients in both series either improved or remained stable, and no deaths were attributed to RBILD. Steroids were given to a few patients, and were associated with apparently beneficial results.

AIP

The clinical findings reported in four series containing well-documented cases of AIP are summarized in Table 8. Hamman and Rich (5), in 1944, provided the first description of this entity, which they termed "acute diffuse interstitial fibrosis." The clinical and pathologic features of their cases are described in meticulous detail, and review of original microscopic slides by Olson and colleagues (17) confirmed the

TABLE 7

CLINICAL FINDINGS IN REPORTED CASES OF DIP AND RBILD

Author, Year	Diagnosis	No. Patients	M/F	Average Age (*yr*; *range*)	Presentation	Chest X-ray	Outcome	Comments
Liebow and colleagues, (40), 1965	DIP	18	10/8 (1.25:1)	45 (16–63)	Dyspnea (all), cough (14 of 18), clubbing (5 of 18)	Ground glass (10 of 18), nodular-linear (3 of 18)	All alive, 12/18 stable or improved	Original description
Gaensler and colleagues (39), 1966	DIP	12	7/5 (1.4:1)	39 (17–65)	Dyspnea (all), cough (9 of 12), clubbing (6 of 12)	Ground glass (9 of 12); minimal changes in 2	10/12 stable or improved, 1 died, 1 worse	All slides reviewed by Liebow
Patchefsky and colleagues (52), 1973	DIP	14	8/6 (1.3:1)	49 (30–66)	Dyspnea (11 of 14), cough (6 of 14), 3 asymptomatic, clubbing (7 of 14)	Nodular-linear interstitial pattern; no ground glass	3/14 died, 1 progressive, 9 stable or improved	Liebow's criteria for diagnosis not followed
Tubbs and colleagues (51), 1977	DIP	26	17/9 (1.9:1)	52 (24–75)	Dyspnea (23 of 26), clubbing (12 of 26)	Reticulonodular, interstitial; bibasilar (6 or 26)	9/23 progressed (3 died); 13/23 improved	Liebow's criteria for diagnosis not followed; only 17 of 26 had open lung biopsies
Carrington and colleagues (30), 1978	DIP	40	28/12 (2.3:1)	42 (17–67)	Not stated	Ground glass (10 of 40), basilar (4 of 40), linear (29 of 40)	11/40 died (27.5%), mean survival 12 yr	Included some cases with fibrosis and honey-comb change
Yousem and colleagues (33), 1989	DIP	36	26/10 (2.6:1)	42 (17–67)	Dyspnea (29 of 34), Cough (26 of 32), asymptomatic (5 of 34), clubbing (15 of 36)	Reticulonodular (32 of 36), ground glass (16 of 36), normal (4)	8/25 (32%) died	Cases previously included in reports by Gaensler and colleagues (13) and Carrington and colleagues (37)
Myers and colleagues (32), 1987	RBILD	6	5/1 (5:1)	36 (28–46)	Cough (5 of 6), asymptomatic (1 of 6)	Reticulonodular (4 of 6), linear (1 of 6), bibasilar atelectasis (1 of 6)	All improved or stable	Original description
Yousem and colleagues (33), 1989	RBILD	18	10/8 (1.25:1)	36 (22–53)	Dyspnea (12 of 18), cough (9 of 18), asymptomatic (1 of 18)	Reticular/reticulonodular (13 of 18), normal (5 of 18), no ground glass	All improved or stable	8 cases previously reported by Gaensler and colleagues (13) and Carrington and colleagues (37) as DIP

Definition of abbreviations: DIP = desquamative interstitial pneumonia; RBILD = respiratory bronchiolitis interstitial lung disease.

diagnosis. Although Primack and associates (34) included three patients who probably should not have been diagnosed as having AIP (two with a history of UIP and one with lupus), their remaining six cases fit well with this entity. The cases of "rapidly fatal pulmonary fibrosis" reported by Pratt and coworkers (55) probably represent diseases other than AIP, and are not included in this analysis. Although these patients manifested a rapidly progressive, fatal interstitial pneumonia at least five of the 12 had underlying connective-tissue diseases, and other potential etiologies were noted in two others. Additionally, the pathologic changes are not well described. Ashbaugh and Maier (56) reported 10 patients with "idiopathic pulmonary fibrosis in adult respiratory distress syndrome." These cases appear to represent organizing diffuse alveolar damage (DAD) resulting from an identifiable acute injury (trauma in eight cases, surgery in one, and kidney transplantation in one) rather than AIP.

There is no apparent sex predilection of AIP. The mean age at onset of all reported cases is 49 yr, but patients from 7 to 77 yr old have been described. The patients reported by Katzenstein and coworkers (16) were considerably younger than those in other studies, however, with a mean age of 28 yr, and five of eight were less than 30 yr old. The onset is acute, with dyspnea followed by the rapid development of respiratory failure in all cases, a clinical presentation and course that fit into the spectrum of the adult respiratory distress syndrome (ARDS). An acute viral-like prodrome precedes the onset of AIP in most individuals, and fever is present in nearly half of cases at presentation. Chest radiographs show bilateral air space opacities that are usually diffuse, and ground-glass attenuation has been noted on CT examination. Mortality rates are high, ranging from 50% to 88% (average: 62%) if cases diagnosed at autopsy are excluded, and the mean length of survival is short, with most deaths occurring within 1 to 2 mo. Patients have been treated with various antibiotics and antiviral agents and often with steroids, but no therapeutic advantage has been demonstrated with any specific mode of therapy (17).

NSIP

Although first described in 1994 (18), NSIP is not a new entity. Moolman and associates (57) reported five patients with an interstitial pneumonia that differed from typical cryptogenic fibrosing alveolitis because of "minimal to mild fibrosis and a prominent lymphoid infiltrate." These cases appear to fit with NSIP. Most similar examples before 1994, however, have probably been included under the categories of IPF or UIP.

Like most other interstitial pneumonias, NSIP occurs mainly in middle-aged adults (Table 9) (18, 44, 58). The average age at onset is 49 yr, although individuals at both extremes of life can be affected. Unlike UIP, NSIP may occur in children, and five of Katzenstein and Fiorelli's (18) patients were younger than 20 yr. There is a slight female predominance of NSIP with a male-to-female ratio of 1:1.4. Dyspnea and cough are the most common presenting complaints, and the average duration of symptoms before biopsy is approximately 8 mo. Fever was present in 22% of patients in Katzenstein and Fiorelli's study (18). Radiographically, bilateral interstitial infiltrates are observed most often, although normal chest radiographs have been noted in six of 85 reported patients (18, 44, 58). Bilateral, patchy areas of ground-glass attenuation are characteristic CT findings (58).

The prognosis in NSIP is generally good. Only 11% of 48 patients with follow-up in Katzenstein and Fiorelli's study died of disease, whereas nearly half (45%) recovered completely, and 42% remained stable or improved (the latter figure includes three patients dying of other causes who had sta-

TABLE 8

CLINICAL FINDINGS IN ACUTE INTERSTITIAL PNEUMONIA

Author, Year	No. Cases	M/F	Average Age (*yr*; *range*)	Presentation	Chest X-ray	Mode of Diagnosis	Outcome (*length of survival*)
Hamman and Rich (5), 1944	4	1/3	43 (21–68)	Dyspnea (all), fever (3 of 4)	Bilateral infiltrates (all), cardiomegaly (1 of 4)	Autopsy (all)	All died, mean survival 1.7 mo (20 d–3 mo)*
Katzenstein and colleagues (16), 1986	8	3/5	28 (13–50)	Dyspnea (all), fever (4 of 8), viral-like prodrome (6 of 8)	Diffuse, bilateral infiltrates	OLB (all)	7 of 8 (88%) died, mean survival 2 mo (23 d–6 mo)
Olsen and colleagues (17), 1990	29	14/15	50 (7–77)	Dyspnea + cough (all), fever (10 of 29), viral-like prodrome (all)	Bilateral infiltrates	OLB (24), autopsy (5)	17 of 29 (59%) died, mean survival 24 d (1 d–4.5 mo)
Primack and colleagues (34), 1993	9	7/2	65 (46–83)	Acute respiratory failure	Bilateral airspace opacities	OLB (4), TBB (1), autopsy (4)	8 of 9 (89%) died, survival less than 3 mo in all

Definition of abbreviations: OLB = open lung biopsy; TBB = transbronchial biopsy.
* Survival based on time from hospitalization to death.

ble lung disease after 17 to 36 mo) (18). The prognosis appears to depend on the extent of fibrosis, since five of 26 (19%) patients with fibrosis in Katzenstein and Fiorelli's study (18) died, compared with none of 22 with inflammation but no fibrosis, although one of the latter patients experienced progressive disease. Mortality rates were higher in Bjoraker and colleagues' study (44), but those cases were not stratified as to degree of fibrosis, and the overall median survival was greater than 13 yr. Interestingly, there were no deaths among the seven patients reported by Park and associates (58), but the mean duration of follow-up was only 7.5 mo. Most patients in Katzenstein and Fiorelli's study were treated with corticosteroids with beneficial results (18). The few patients with progressive disease additionally received cytotoxic therapy with either cyclophosphamide or azathioprine, generally to no avail.

A number of potential etiologies or associated conditions were identified in Katzenstein and Fiorelli's (18) study. Connective-tissue diseases, including rheumatoid arthritis, systemic lupus erythematosus, polymyositis, scleroderma, and Sjogren's syndrome, were present in 10 of 64 patients (16%) (18). One case of NSIP was subsequently found to be related to exposure to a pet parrot, thus representing a form of hypersensitivity pneumonia. Several other potential exposure sources were noted in a few patients, including a canary, wood stove, grain dust, coal and ash, and farming, but a definate relationship to disease could not be proven (18). Two patients were receiving drugs that have been associated with pulmonary toxicity, including hydralazine, gold, and penicillamine, although clinically neither patient was thought to have drug toxicity (18). Five patients had a history of probable recent acute lung injury (2 wk to 4 mo previously), including pneumonia (two patients), ARDS (two patients), and coronary artery bypass surgery (one patient), and they were biopsied because of persistent lung infiltrates (18). None of the patients was known to be immunocompromised.

GRADING OF "CELLULARITY" AND FIBROSIS

Rather than subclassifying IPF into pathologic entities, most investigators have attempted to grade the amount of fibrosis and cellularity and to correlate the results with the response to therapy and prognosis. The results of 12 of these studies published since 1972 are summarized in Table 10. The widely held view that cellular biopsies are associated with a greater likelihood of response to corticosteroids and a better prognosis has emanated from these studies, but upon critical examination there is little support for this conclusion. One problem is that the term "cellularity" has often been used indiscriminately for interstitial inflammation, intraalveolar macrophage accumulation, or a combination of both. Another problem is that conclusions in some studies were based either on small numbers of cases or on the findings in percutaneous needle or transbronchial rather than open-lung biopsy specimens.

Scadding and Hinson (7) were among the earliest investigators to suggest a better response to steroids in patients having a cellular histology in IPF than in patients with fibrosis and little cellularity. They equated cellularity with intraalveolar macrophage accumulation. Their conclusion, however, was based on only 16 patients with open-lung biopsy specimens, and no correlation was found between histologic features and dura-

TABLE 9

CLINICAL FEATURES OF REPORTED PATIENTS WITH NSIP

Author	No. of Patients	M/F	Average Age (*yr*; *range*)	Symptoms	Mean Duration of Symptoms (*range*)	Outcome
Katzenstein and Fiorelli (18)	64	26/38 (1:1.5)	46 (9–78)	Dyspnea (80%), cough (33%), fever (22%)	8 mo (0.25–60)	5 of 48 (11%) with follow-up died (mean length of survival 16 mo)
Park and colleagues (58)	7	1/6	55 (43–61)	Dyspnea (all), cough (3 of 7)	9 mo (1–36)	6 of 7 improved after 1–15 mo follow-up (mean 7.5 mo); 1 stable
Bjoraker and colleagues (44)	14	8/6 (1.3:1)	57 (40–73)	Dyspnea (all), cough (85%)	15 mo	Median survival 13.5 yr

Definition of abbreviations: NSIP = nonspecific interstitial pneumonia.

tion of life. Similar observations about steroid responsiveness were reported by Dreisin and coworkers (59), based on 12 patients with short (3- to 6-mo) periods of follow-up. Their "cellular" cases included examples of UIP, DIP, and LIP, and from their description probably also NSIP. Although Turner–Warwick and associates (12) reported that greater cellularity was associated with longer survival, the difference was not significant when corrected for patient age and sex. Turner–Warwick and associates examined open-lung biopsy specimens from 42 patients (12), lumping together both UIP and DIP,

TABLE 10

SERIES CORRELATING PATHOLOGIC FINDINGS IN IPF WITH RESPONSE TO THERAPY OR SURVIVAL

Author, Year	No. of Cases	Mean Age, (*yr*; *range*)	Type of Biopsy	Pathologic Features Examined	Findings	Comments
Scadding and Hinson (7), 1967	16	45 (12–63)	OLB (16)	Alveolar wall thickening, uniformity, alveolar macrophages, lymphoid follicles	Slight alveolar wall thickening with many intraalveolar macrophages has better response to steroids than severe thickening; no correlation between histologic features and duration of life	Probably includes DIP, UIP, and NSIP. "Thickening" not defined (presumably is fibrosis)
Stack and colleagues (23), 1972	96	Not stated (median approximately 60–69)	OLB (24), Drill (6)	Cellularity (interstitial inflammation and alveolar macrophages), fibrosis	Most patients with cellular histology (6 of 9) responded to corticosteroids compared with none (0 of 6) with fibrosis and little cellularity (1 of 7 not treated)	Only 30 of 96 patients biopsied, only 16 biopsies reviewed
DeRemee and colleagues (19), 1972	81	55 (16–79)	TBB (81)	Interstitial inflammation and fibrosis	Severe fibrosis associated with slightly decreased survival in women, no affect in men	No OLBs; Included 10 rheumatoid arthritis patients, 5 patients on nitrofurantoin
Carrington and colleagues (30), 1978	93	DIP-42 (17–67) UIP-51 (15–72)	OLB (86), Autopsy (7)	DIP versus UIP, extent of fibrosis	Longer survival, lower mortality, better response to steroids in DIP; extensive fibrosis associated with worse prognosis in both UIP and DIP	Included 1 case of nitrofurantoin lung, 1 procainamide lung, 16 associated collagen vascular disease; probably also included some NSIP and RBILD
Dreisin and colleagues (59), 1978	24	Not stated	TBB (13) OLB (11)	Cellularity, fibrosis, immune complexes	Response to steroids in 7 of 8 cellular with circulating immune complexes compared with 1 of 4 fibrotic without circulating immune complexes	No long-term follow-up. 3–6 mo follow-up in only 12 of 24. Includes UIP, DIP, LIP and probably NSIP cases
Winterbauer and colleagues (11),1978	20	59 (28–79)	OLB (20)	20 histologic variables, attempted to classify in Liebow categories	Response to therapy inversely related to degree of interstitial fibrosis; no relationship to inflammation or intraalveolar macrophages; could not clearly separate into Liebow categories	Includes mixture of different diseases, probably NSIP, BOOP, drug reactions, etc.; 13 of 20 had rapidly progressive disease; 2 had nitrofurantoin lung, 2 had lymphoma one of whom received BCNU
Turner–Warwick and colleagues (12), 1980	220	58 (19–84)	OLB (50) Drill/ needle (16) Autopsy (52)	Degree of fibrosis, lung destruction, inflammation, overall cellularity	Greater cellularity associated with longer survival (not significant when corrected for age and sex). Trend toward steroid responsiveness with cellular biopsy	Only 42 OLB reviewed; "cellular" included both alveolar macrophages and mural inflammation. Includes UIP, DIP, end-stage lung, probably also NSIP
Wright and colleagues (60), 1981	62	57	Trephine (62/62)	Alveolar/interstitial inflammation, fibrosis, cellularity	Cellularity correlated with young age; response to steroids associated with alveolar macrophages and less fibrosis; worse survival associated with more fibrosis	No OLB. Included 5 patients less than 40 yo and 2 cases of DIP
Tukiainen and colleagues (20), 1983	100	53 (16–77)	Needle (50), TBB (1) OLB (13), Autopsy (6)	Thickness of alveolar walls, extent of inflammation/ fibrosis, degree of fibroblast activity	Better response to steroids and better prognosis over 4 yr in group with mainly inflammation, but no significant difference in survival	64 biopsies reviewed (only 13 OLB); probably includes NSIP, BOOP; associated collagen vascular disease in 33 of 100
Gelb and colleagues (61), 1983	20	58 (31–86)	OLB (20)	Cellularity versus fibrosis; DIP versus UIP	Diffuse fibrosis associated with uniformly poor prognosis, but cellularity not associated with steroid responsiveness. DIP better prognosis	Small number of cases lumped UIP + DIP as "cellular" with short follow-up
Watters and colleagues (45), 1987	26	57	OLB (26)	11 pathologic abnormalities graded	Prominent alveolar-septal inflammation + absent to mild honeycomb change associated with steroid response	Small number of cases; probably also includes NSIP
Raghu and colleagues (49), 1991	27	56	OLB (23) TBB (4)	Degree of fibrosis	Mild fibrosis associated with functional improvement at 1 yr not with survival	Small number of cases; type of fibrosis not specified

Definition of abbreviations: DIP = desquamative interstitial pneumonia; IPF = idiopathic pulmonary fibrosis; OLB = open-lung biopsy; BOOP = bronchiolitis obliterans-organizing pneumonia; NSIP = nonspecific interstitial pneumonia; UIP = usual interstitial pneumonia; BCNU = bis-chloroethyl-nitrosourea; TBB = transbronchial biopsy.

and probably also including NSIP cases. Although they evaluated a number of individual histologic parameters, the assessment of overall cellularity included a combination of interstitial inflammation and intraalveolar macrophage accumulation. Turner–Warwick and associates also studied steroid responsiveness relative to histologic features in 32 treated patients (46). No definite discriminating features were detected between the responders and nonresponders, although slightly more responders (10 of 18, or 56%) had cellular biopsies as compared with nonresponders (four of 14, or 29%). Gelb and associates (61) similarly evaluated both interstitial and intraalveolar cellularity together, but on the basis of examination of 20 cases, concluded that cellularity was not associated with steroid responsiveness. They included examples of both UIP and DIP in their cellular cases, and noted a better prognosis for their three DIP cases. Tukiainen and colleagues (20) assessed interstitial inflammation specifically, and noted a better response to steroids and improved prognosis in patients who mainly had inflammation. Only 13 of the 64 cases examined, however, had open-lung biopsies; the majority (4) had needle biopsies, and one had a transbronchial biopsy. From Tukiainen and colleagues' description and their illustrations, it seems likely that examples of NSIP and BOOP were included in their cases. Wright and coworkers (60) based their conclusions entirely on the results of trephine biopsies. They found that large numbers of intraalveolar macrophages and little fibrosis were associated with a better response to steroids. However, cellularity and prognosis also correlated with young age. Watters and colleagues (45) supplied the most intricate pathologic study of IPF, evaluating 11 separate histologic features. These investigators correlated bronchoalveolar lavage fluid (BALF) lymphocytosis with alveolar septal inflammation and minimal honeycomb change, and also with prognosis. Only 19 patients, however, were available for follow-up at 1 yr; of these, five of seven with BALF lymphocytosis (most of whom presumably had alveolar septal inflammation with minimal honeycomb change) improved, compared with none of 12 patients without BALF lymphocytosis, although nine of the latter remained stable and only three deteriorated.

There is slightly stronger evidence for an association of advanced fibrosis and honeycomb lung with lack of steroid responsiveness and a poorer prognosis. This association should not be surprising, since end-stage fibrosis with lung restructuring is not a reversible change. Carrington and colleagues' (30) study of 93 patients is probably the most informative in this regard. They noted a worse prognosis in both UIP and DIP patients when extensive fibrosis was present. Importantly, however, DIP patients, when stratified for similar amounts of fibrosis, retained a better prognosis than did UIP patients. Both Scadding and Hinson (7) and Stack and associates (8) reported a lack of response to steroid therapy in four patients with extensive fibrosis, although this conclusion was based on only seven patients in each study. Gelb and coworkers (61) reported worsening disease or death despite steroid therapy in four patients with extensive fibrosis. Winterbauer and colleagues (11) indicated that the degree of interstitial fibrosis was the single most important variable in predicting response to therapy. Their 20 cases, however, comprised a mixture of unrelated and noncomparable interstitial processes, including NSIP, BOOP, and drug reactions. Raghu and coworkers (62) noted improved lung function at 1 yr in patients with mild fibrosis, but there was no difference in survival related to degree of fibrosis; five of 10 patients having mild fibrosis were alive, compared with three of 13 with moderate to severe fibrosis. Moreover, the treatment of these patients varied from steroids alone to steroids plus azathioprine.

With the exception of Carrington and colleagues' (30) study, none of these studies examined the degree of fibrosis or cellularity separately for the individual pathologic forms of IPF. However, this type of analysis was performed by Katzenstein and Fiorelli (18) in cases of NSIP in which pure inflammation was associated with the best prognosis and pure fibrosis had the poorest prognosis. Clearly, additional studies need to be undertaken in pathologically confirmed cases of UIP and DIP. AIP, by virtue of its relatively constant histologic appearance and its active, fibroblastic type of fibrosis, however, is not relevant to this type of examination.

RELATIONSHIP OF UIP AND DIP

There has been controversy for years regarding the relationship of UIP and DIP. Although the pathologic features of these two diseases are quite different, the opinion is held in some circles that DIP represents an early stage of UIP. We believe that the evidence, as presented in previous sections, argues otherwise. Several commonly held misconceptions, however, may contribute to the reluctance to accept DIP and UIP as separate entities, and these are discussed in the following sections.

The Greater Cellularity of DIP than of UIP Indicates that DIP Represents an Early Stage of UIP

The fault in this reasoning lies in the fact that there are no data to support the assumption that the histologic appearance of UIP in its early stage is any more cellular than in the later stage. The earliest change in UIP, in fact, is the fibroblast focus, characterized by a distinct cluster of fibroblasts and myofibroblasts within the alveolar wall, and there is little associated interstitial inflammation or intraalveolar macrophage accumulation. Both electron microscopy and immunohistochemistry have shown that fibroblast foci represent microscopic zones of acute lung injury in which alveolar lining cells are destroyed and the epithelial basement membrane is denuded (29, 35, 36). The fibroblast proliferation occurs in an attempt to repair the damaged alveolus. The process evolves over 1 to 2 wks, and is followed by collagen deposition within a few months. Although scattered mononuclear inflammatory cells may accompany the process, neither interstitial inflammation nor intraalveolar macrophage accumulation are major features.

Another argument against the idea that DIP represents an early stage of UIP is that there is no good evidence that DIP (or any other idiopathic interstitial pneumonia) ever progresses to UIP. Recent serial radiographic studies of these two diseases, in fact, emphasize that the characteristic CT features of each remain distinct over time (53, 54). Likewise, sequential biopsy specimens examined in several DIP patients after intervals ranging from 1 to 12 yr remained unchanged except for mildly increased fibrosis in a few (30, 39, 51, 63, 64). Although the development of severe interstitial fibrosis was described in one patient after an interval of 4 yr, the initial biopsy specimen in this individual was a trephine biopsy, a method that cannot be used to reliably diagnose DIP (51).

DIP Is Indistinguishable from UIP at Autopsy, and Therefore DIP Represents a Histologic Variant of UIP

This commonly held misconception is based on Patchefsky and coworkers' (52) report that severe interstitial fibrosis and honeycomb lung without features of DIP were found at autopsy in three patients previously diagnosed as having DIP. These authors' criteria for diagnosing DIP were not well defined; at least one patient appears to have had hard-metal

pneumoconiosis, and others may have had UIP rather than DIP. Honeycomb change without specific diagnostic features has also been noted in a few other autopsies of DIP patients (30, 39, 64). This lesion is a nonspecific type of lung scarring that results from a variety of interstitial processes, and it carries few implications by itself about the nature of the initial lung disease. It is interesting, however, that although features of DIP may be lost at autopsy in some cases, diagnostic features of UIP are usually maintained at autopsy, despite the presence of honeycomb change (30).

DIP Is Not a Specific Disease because Changes Resembling DIP (DIP-like Reactions) Occur in a Wide Variety of Unrelated Conditions

Bedrossian and colleagues (65) reported six examples of space-occupying pulmonary lesions (one each of hamartoma, lymph-node, and rheumatoid nodule, and three cases of eosinophilic granuloma) that were surrounded by prominent intraalveolar macrophage accumulation. This parenchymal reaction resembled DIP, except that it was localized rather than diffuse. Bedrossian and colleagues coined the term "DIP-like reaction," and it has since gained wide acceptance. Although it is true that DIP-like reactions commonly occur in many different situations, including UIP, their occurrence by no means invalidates the diagnosis of the disease entity of DIP. A DIP-like reaction is usually easily distinguished from DIP once the pathologic features of the primary underlying lung lesion are recognized. In DIP itself, however, there are no other findings to explain the widespread intraalveolar accumulation of macrophages.

The lack of specificity of intraalveolar macrophage accumulation for DIP has been used by some investigators as evidence against the existence of DIP as a specific disease entity. It should be remembered, however, that inflammation and fibrosis, the histologic hallmarks of UIP, are also nonspecific reactions that occur in a wide assortment of lung diseases, yet few question the existence of UIP as a disease. In a similar fashion, the occurrence of granulomas in many different diseases does not negate the existence of sarcoidosis. It is only in the appropriate clinical and histologic context that any of these findings gains specificity. Diagnosis of the interstitial pneumonias, therefore, like the diagnosis of many other lung diseases, requires not only careful pathologic examination, but also correlation of clinical, laboratory, and radiographic findings with pathologic findings.

RELATIONSHIP OF AIP AND UIP

The distinct pathologic features of AIP have been appreciated only recently. Previously, in the pathology literature, AIP was considered to represent an acute variant of UIP, whereas in the clinical literature it was included under the category of IPF. The reason that these diseases have traditionally been lumped together relates to their sharing of the common pathologic findings of inflammation and fibrosis, and to the failure of most previous investigators to recognize the important differences in the nature of the fibrosis. In AIP, the fibrosis is active and temporally uniform, characterized by fibroblast proliferation and little collagen deposition. UIP differs in that the fibrosis is mainly inactive and composed of collagen with few fibroblasts, although there are scattered, microscopic foci of fibroblast proliferation (fibroblast foci). These fibroblast foci are histologically identical to the diffuse fibroblast proliferation of AIP, differing from the latter only in extent, and both have been shown by electron microscopy and immunohistochemistry to represent manifestations of prior acute lung injury (6, 16, 27, 29, 35). In AIP the acute injury is massive, involving a large portion of parenchyma and occurring during a single period of time, whereas in UIP the acute injury is very focal, affecting widely scattered portions of lung but occurring and recurring over many years (Figure 10). The subsequent course of these diseases reflects these differences in extent and time course of the acute lung injury. UIP is progressive because of continuing and recurring injury, and the characteristic temporal heterogeneity noted histologically is explained by the different time of onset of the injuries. Because of the large area of lung injured in AIP, early mortality is high, but if the patient survives the initial trauma, recovery can occur. Recurrent injury is not a feature in AIP, and therefore the course is not progressive.

SIGNIFICANCE OF NSIP—A SPECIFIC DISEASE OR A HISTOLOGIC MANIFESTATION OF MANY DISEASES?

The concept of NSIP was initially created as a repository for difficult-to-classify interstitial pneumonias, in order to alleviate the pressure on pathologists to fit every case into the categories UIP, DIP, or AIP. The main intent in its creation was to prevent the overdiagnosis of UIP because of the grim prognosis and the frequent use of cytotoxic therapy in this disease. Initially, therefore, NSIP was considered a wastebasket term for a variety of nonclassifiable interstitial pneumonias, rather than representing a distinct disease. Associated conditions, especially collagen-vascular diseases, and various etiologies such as drug reactions or hypersensitivity pneumonia were identified in a few cases. It has become clear, however, that many cases fit into a similar clinical spectrum and that an etiology is often not identifiable. Thus, the initial concept of NSIP as a mixture of entities has evolved into NSIP as a clinicopathologic entity. The situation is analogous to that associated with BOOP, which may be a manifestation of a wide variety of causes, yet which also occurs as an idiopathic disease.

The importance of careful correlation of the radiographic and clinical findings with the pathologic findings in making the diagnosis of NSIP cannot be overemphasized. Some examples of NSIP containing extensive fibrosis may represent inadequately sampled and thus undiagnosable UIP. Biopsy in cases with clinical and radiographic features strongly suggestive of UIP may therefore be more appropriately considered as consistent with UIP rather than being diagnosed as NSIP.

A histologic reaction somewhat resembling NSIP may occur in immunocompromised persons, including, for example,

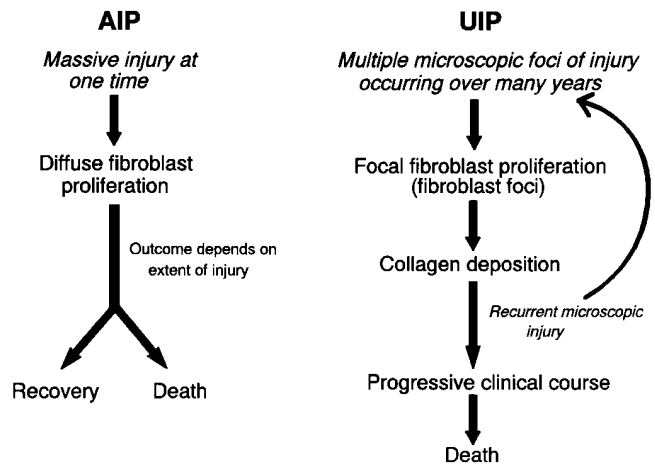

Figure 10. Contrasting pathogenesis and course of AIP and UIP.

individuals with AIDS, bone-marrow transplant recipients, and persons receiving various chemotherapeutic agents (15, 66). Many of these cases represent manifestations of difficult-to-diagnose viral or other infections, or result from lung injury of various causes. Their clinical presentation reflects these etiologies, and is usually that of an acute febrile illness. Unfortunately, the term "nonspecific interstitial pneumonia" has sometimes been applied to these reactions (66). We believe, however, that this term should be restricted to the relatively uniform clinicopathologic entity as described previously and which occurs in immunocompetent individuals.

SUMMARY AND CONCLUSIONS

1. Four pathologically distinct interstitial pneumonias comprise the clinical syndrome of IPF. The past inclusion of these different entities under a single designation may explain the perplexing variation in presentation, response to steroid therapy, and clinical course that has been noted in patients with IPF.
2. The fact that all the idiopathic interstitial pneumonias are characterized histologically by varying amounts of inflammation and fibrosis explains why they have previously been lumped together under a single designation. Recognition of qualitative differences in the nature of the fibrosis as well as appreciation of the temporal characteristics of the changes, allows their distinction from one another.
3. The term "idiopathic pulmonary fibrosis" should be reserved for cases of UIP, the most common idiopathic interstitial pneumonia. This disease has an insidious onset, is chronically progressive, usually does not respond to therapy, and is fatal in most cases.
4. DIP is a rare form of idiopathic interstitial pneumonia that has an insidious onset and a good prognosis. It maybe related to cigarette smoking. Consideration should be given to replacing the anatomically inaccurate and controversial term "desquamative interstitial pneumonia" with RBILD, which is anatomically more appropriate and conveys pathogenetic implications.
5. AIP is an acute, fulminant form of idiopathic interstitial pneumonia that corresponds to the cases described by Hamman and Rich in 1944 (21). The course is rapid, evolving over several months, and the mortality rates are high. The pathologic changes are a manifestation of severe, extensive acute lung injury.
6. NSIP is a temporally uniform interstitial pneumonia that does not fit histologically with any other idiopathic interstitial pneumonia. Interstitial inflammation is often prominent, and the prognosis is generally good with a beneficial response to steroids in most patients.
7. There has been a longstanding misconception that UIP evolves from an early "cellular" lesion into a later fibrotic state. The earliest change in UIP is the fibroblast focus, a manifestion of acute lung injury. Interstitial inflammation and intraalveolar macrophage accumulation, if they occur at all, are secondary events.
8. There has been considerable emphasis on the grading of cellularity and fibrosis in IPF, because of potential prognostic implications. The evidence suggests that the division of IPF into the four forms of idiopathic interstitial pneumonia is more important prognostically than any one grading system. However, within each category of disease, the extent of fibrosis appears to have significance. The relative roles of the different types of fibrosis (collagen versus fibroblast foci) in determining prognosis have not yet been examined.
9. Acceptance of this pathologic classification of the idiopathic interstitial pneumonias has important implications for future clinical and basic-science investigations of IPF, as well as for understanding patient prognosis and treatment.

References

1. Cherniack, R. M., R. G. Crystal, and A. R. Kalica. 1991. Current concepts in idiopathic pulmonary fibrosis: a road map for the future. *Am. Rev. Respir. Dis.* 143:680–683.
2. King, T. E., Jr. 1991. Diagnostic advances in idiopathic pulmonary fibrosis. *Chest* 100:238–241.
3. Marinelli, W. A. 1995. Idiopathic pulmonary fibrosis: progress and challenge. *Chest* 108:297–298.
4. Raghu, G. 1995. Interstitial lung disease: a diagnostic approach. Are CT scan and lung biopsy indicated in every patient? *Am. J. Respir. Crit. Care Med.* 151:909–914.
5. Hamman, L., and A. Rich. 1944. Acute diffuse interstitial fibrosis of the lung. *Bull. Johns Hopkins Hosp.* 74:177–212.
6. Liebow, A. A. 1975. Definition and classification of interstitial pneumonias in human pathology. *Prog. Respir. Res.* 8:1–31.
7. Scadding, J. G., and K. F. W. Hinson. 1967. Diffuse fibrosing alveolitis (diffuse interstitial fibrosis of the lungs): correlation of histology at biopsy with prognosis. *Thorax* 22:291–304.
8. Stack, B. H. R., Y. F. J. Choo-Kang, and B. E. Heard. 1972. The prognosis of cryptogenic fibrosing alveolitis. *Thorax* 27:535–542.
9. Cherniack, R. M., T. V. Colby, A. Flint, W. M. Thurlbeck, J. A. Waldron, Jr., L. Ackerson, M. I. Schwarz, and T. E. King, Jr. 1995. Correlation of structure and function in idiopathic pulmonary fibrosis. *Am. J. Respir. Crit. Care Med.* 151:1180–1188.
10. Crystal, R. G., J. D. Fulmer, W. C. Roberts, M. L. Moss, B. R. Line, and H. Y. Reynolds. 1976. Idiopathic pulmonary fibrosis: clinical, histologic, radiographic, physiologic, scintigraphic, cytologic and biochemical aspects. *Ann. Intern. Med.* 85:769–788.
11. Winterbauer, R. H., S. P. Hammar, K. O. Hallman, J. E. Hays, N. E. Pardee, E. H. Morgan, J. D. Allen, K. D. Moores, W. Bush, and J. H. Walker. 1978. Diffuse interstitial pneumonitis. Clinicopathologic correlations in 20 patients treated with prednisone/azathioprine. *Am. J. Med.* 65:661–672.
12. Turner–Warwick, M., B. Burrows, and A. Johnson. 1980. Cryptogenic fibrosing alveolitis: clinical features and their influence on survival. *Thorax* 35:171–180.
13. Fishman, A. P. 1978. UIP, DIP, and all that. *N. Engl. J. Med.* 298:843–844.
14. Lillington, G. A. 1981. Ban the boomerang. *Chest* 80:122.
15. Katzenstein, A.-L. A. 1997. Katzenstein and Askin's surgical pathology of non-neoplastic lung disease. W.B. Saunders, Philadelphia.
16. Katzenstein, A.-L. A., J. L. Myers, and M. T. Mazur. 1986. Acute interstitial pneumonia: a clinicopathologic, ultrastructural, and cell kinetic study. *Am. J. Surg. Pathol.* 10:256–267.
17. Olsen, J., T. V. Colby, and C. G. Elliott. 1990. Hamman-Rich syndrome revisited. *Mayo Clin. Proc.* 65:1538–1548.
18. Katzenstein, A.-L. A., and R. F. Fiorelli. 1994. Non-specific interstitial pneumonia/fibrosis: histologic patterns and clinical significance. *Am. J. Surg. Pathol.* 18:136–147.
19. DeRemee, R. A., E. G. Harrison, Jr., and H. A. Andersen. 1972. The concept of classic interstitial pneumonitis-fibrosis (CIP-F) as a clinicopathologic syndrome. *Chest* 61:213–220.
20. Tukiainen, P., E. Taskinen, P. Holsti, O. Korhola, and M. Valle. 1983. Prognosis of cryptogenic fibrosing alveolitis. *Thorax* 38:349–355.
21. Agusti, C., A. Xaubet, J. Roca, A. G. N. Agusti, and R. Rodriguez-Roisin. 1992. Interstitial pulmonary fibrosis with and without associated collagen vascular disease: results of a two year follow up. *Thorax* 47: 1035–1040.
22. Baughman, R. P., and E. E. Lower. 1992. Use of intermittent, intravenous cyclophosphamide for idiopathic pulmonary fibrosis. *Chest* 102: 1090–1094.
23. Schwartz, D. A., R. A. Helmers, J. R. Galvin, D. S. van Fossen, K. L. Frees, C. S. Dayton, L. F. Burmeister, and G. W. Hunninghake. 1994. Determinants of survival in idiopathic pulmonary fibrosis. *Am. J. Respir. Crit. Care Med.* 149:450–454.
24. Wells, A. U., P. Cullinan, D. M. Hansell, M. B. Rubens, C. M. Black, A. J. Newman-Taylor, and R. M. Du Bois. 1994. Fibrosing alveolitis associated with systemic sclerosis has a better prognosis than lone

cryptogenic fibrosing alveolitis. *Am J. Respir. Crit. Care Med.* 149:1583–1590.

25. Hanson, D., R. H. Winterbauer, S. H. Kirtland, and R. Wu. 1995. Changes in pulmonary function test results after 1 year of therapy as predictors of survival in patients with idiopathic pulmonary fibrosis. *Chest* 108: 305–310.
26. Katzenstein, A.-L. A. 1985. Pathogenesis of "fibrosis" in interstitial pneumonia: an electron microscopic study. *Hum. Pathol.* 16:1015–1024.
27. Fukuda, Y., F. Basset, V. J. Ferrans, and N. Yamanaka. 1995. Significance of early intraalveolar fibrotic lesions and integrin expression in lung biopsy specimens from patients with idiopathic pulmonary fibrosis. *Hum. Pathol.* 26:53–61.
28. Katzenstein, A.-L. A., J. L. Myers, W. D. Prophet, L. S. Corley, III, and M. S. Shin. 1986. Bronchiolitis obliterans and usual interstitial pneumonia: a comparative clinicopathologic study. *Am. J. Surg. Pathol.* 106: 373–381.
29. Kuhn, C., III, J. Boldt, T. E. King, E. Crouch, T. Vartio, and J. A. McDonald. 1989. An immunohistochemical study of architectural remodeling and connective tissue synthesis in pulmonary fibrosis. *Am. Rev. Respir. Dis.* 140:1693–1703.
30. Carrington, C. B., E. A. Gaensler, R. E. Coutu, M. X. FitzGerald, and R. G. Gupta. 1978. Natural history and treated course of usual and desquamative interstitial pneumonia. *N. Engl. J. Med.* 298:801–809.
31. Guerry-Force, M. L., N. L. Muller, J. L. Wright, B. Wiggs, C. Coppin, P. D. Pare, and J. C. Hogg. 1987. A comparison of bronchiolitis obliterans with organizing pneumonia, usual interstitial pneumonia, and small airways disease. *Am. Rev. Respir. Dis.* 135:705–712.
32. Myers, J. L., C. F. Veal, Jr., M. S. Shin, and A.-L. A. Katzenstein. 1987. Respiratory bronciolitis causing interstitial lung disease: a clinicopathologic study of six cases. *Am. Rev. Respir. Dis.* 135:880–884.
33. Yousem, S. A., T. V. Colby, and E. A. Gaensler. 1989. Respiratory bronchiolitis-associated interstitial lung disease and its relationship to desquamative interstitial pneumonia. *Mayo Clin. Proc.* 64:1373–1380.
34. Primack, S. L., T. E. Hartman, J. Ikezoe, M. Akira, M. Sakatani, and N. L. Müller. 1993. Acute interstitial pneumonia: radiographic and CT findings in nine patients. *Radiology* 188:817–820.
35. Kuhn, C., and J. A. McDonald. 1991. The roles of the myofibroblast in idiopathic pulmonary fibrosis: ultrastructural and immunohistochemical features of sites of active extracellular matrix synthesis. *Am. J. Pathol.* 138:1257–1265.
36. Myers, J. L., and A.-L. A. Katzenstein. 1988. Epithelial necrosis and alveolar collapse in the pathogenesis of usual interstitial pneumonia. *Chest* 94:1309–1311.
37. Bensadoun, E. S., A. K. Burke, J. C. Hogg, and C. R. Roberts. 1996. Proteoglycan deposition in pulmonary fibrosis. *Am. J. Respir. Crit. Care Med.* 154:1819–1828.
38. Wallace, W. A. H., S. E. M. Howie, D. Lamb, and D. M. Salter. 1995. Tenascin immunoreactivity in cryptogenic fibrosing alveolitis. *J. Pathol.* 175:415–420.
39. Gaensler, E. A., A. M. Goff, and C. M. Prowse. 1966. Desquamative interstitial pneumonia. *N. Engl. J. Med.* 274:113–128.
40. Liebow, A. A., A. Steer, and J. G. Billingsley. 1965. Desquamative interstitial pneumonia. *Am. J. Med.* 39:369–404.
41. Valdivia, E., G. Hensley, J. Wu, E. P. Leroy, and W. Jaeschke. 1977. Morphology and pathogenesis of desquamative interstitial pneumonitis. *Thorax* 32:7–18.
42. Niewoehner, D. E., J. Kleinerman, and D. B. Rice. 1974. Pathologic changes in the peripheral airways of young cigarette smokers. *N. Engl. J. Med.* 291:755–758.
43. Churg, A., J. Golden, S. Fligiel, and J. C. Hogg. 1983. Bronchopulmonary dysplasia in the adult. *Am. Rev. Respir. Dis.* 127:117–120.
44. Bjoraker, J. A., J. H. Ryu, M. K. Edwin, J. L. Myers, H. D. Tazelaar, D. R. Schroeder, and K. P. Offord. 1998. Prognostic significance of histopathological subsets in idiopathic pulmonary fibrosis. *Am. J. Respir. Crit. Care Med.* 157:199–203.
45. Watters, L. C., M. I. Schwarz, R. M. Cherniack, J. A. Waldron, T. L. Dunn, R. E. Stanford, and T. E. King. 1987. Idiopathic pulmonary fibrosis: pretreatment bronchoalveolar lavage cellular constituents and their relationships with lung histopathology and clinical response to therapy. *Am. Rev. Respir. Dis.* 135:696–704.
46. Turner–Warwick, M., B. Burrows, and A. Johnson. 1980. Cryptogenic fibrosing alveolitis: response to corticosteroid treatment and its effect on survival. *Thorax* 35:593–599.
47. Hunninghake, G. W., and A. R. Kalica. 1995. Approaches to the treatment of pulmonary fibrosis. *Am. J. Respir. Crit. Care Med.* 151:915–918.
48. Johnson, M. A., S. Kwan, N. J. C. Snell, A. J. Nunn, J. H. Darbyshire, and M. Turner-Warwick. 1989. Randomized controlled trial comparing prednisolone alone with cyclophosphamide and low dose prednisolone in combination in cryptogenic fibrosing alveolitis. *Thorax* 44: 280–288.
49. Raghu, G. 1997. Idiopathic pulmonary fibrosis: a need for treatment with drugs other than corticosteroids—a role for antifibrotic agents? *Mayo Clin. Proc.* 72:285–287.
50. Douglas, W. W., J. H. Ryu, J. A. Bjoraker, D. R. Schroeder, J. L. Myers, H. D. Tazelaar, S. J. Swensen, P. D. Scanlon, S. G. Peters, and R. A. DeRemee. 1997. Colchicine versus prednisone as treatment of usual interstitial pneumonia. *Mayo Clin. Proc.* 72:201–209.
51. Tubbs, R. R., S. P. Benjamin, N. E. Reich, L. J. McCormack, and H. S. Van Ordstrand. 1977. Desquamative interstitial pneumonitis: cellular phase of fibrosing alveolitis. *Chest* 72:159–165.
52. Patchefsky, A. S., H. L. Israel, W. S. Hoch, and G. Gordon. 1973. Desquamative interstitial pneumonia relationship to interstitial fibrosis. *Thorax* 28:680–693.
53. Akira, M., S. Yamamoto, H. Hara, M. Sakatani, and B. Ueda. 1997. Serial computed tomographic evaluation in desquamative interstitial pneumonia. *Thorax* 52:333–337.
54. Hartman, T. E., S. L. Primack, E.-Y. Kang, S. J. Swensen, D. M. Hansell, G. McGuinness, and N. L. Müller. 1996. Disease progression in usual interstitial pneumomia compared with desquamative interstitial pneumonia: assessment with serial CT. *Chest* 110:378–382.
55. Pratt, D., M. I. Schwartz, J. J. May, and R. B. Dreisin. 1979. Rapidly fatal pulmonary fibrosis: the accelerated variant of interstitial pneumonitis. *Thorax* 34:587–593.
56. Ashbaugh, D. G., and R. V. Maier. 1985. Idiopathic pulmonary fibrosis in adult respiratory distress syndrome: diagnosis and treatment. *Arch. Surg.* 120:530–535.
57. Moolman, J. A., P. G. Bardin, D. J. Rossouw, and J. R. Joubert. 1991. Cyclosporin as a treatment for interstitial lung disease of unknown aetiology. *Thorax* 46:592–595.
58. Park, J. S., K. S. Lee, J. S. Kim, C. S. Park, Y.-L. Suh, D. L. Choi, and K. J. Kim. 1995. Nonspecific interstitial pneumonia with fibrosis: radiographic and CT findings in seven patients. *Radiology* 195:645–648.
59. Dreisin, R. B., M. I. Schwarz, A. N. Theofilopoulos, and R. E. Stanford. 1978. Circulating immune complexes in the idiopathic interstitial pneumonias. *N. Engl. J. Med.* 298:353–357.
60. Wright, P. H., B. E. Heard, S. J. Steel, and M. Turner-Warwick. 1981. Cryptogenic fibrosing alveolitis: assessment by graded trephine lung biopsy histology compared with clinical, radiographic, and physiological features. *Br. J. Dis. Chest* 75:61–70.
61. GeIb, A. F., R. B. Dreisen, J. D. Epstein, J. D. Silverthorne, Y. Bickel, M. Fields, W. A. Border, and C. R. Taylor. 1983. Immune complexes, gallium lung scans, and bronchoalveolar lavage in idiopathic interstitial pneumonitis-fibrosis: a structure-function clinical study. *Chest* 84: 148–153.
62. Raghu, G., W. J. Depaso, K. Cain, S. P. Hammar, C. E. Wetzel, D. F. Dreis, J. Hutchinson, N. E. Pardee, and R. H. Winterbauer. 1991. Azathioprine combined with prednisone in the treatment of idiopathic pulmonary fibrosis: a prospective double-blind, randomized, placebo-controlled clinical trial. *Am. Rev. Respir. Dis.* 144:291–296.
63. Lipworth, B., A. Woodcock, B. Addis, and M. Turner-Warwick. 1987. Late relapse of desquamative interstitial pneumomia. *Am. Rev. Respir. Dis.* 136:1253–1255.
64. McCann, B. G., and D. B. Brewer. 1974. A case of desquamative interstitial pneumonia progressing to "honeycomb lung." *J. Pathol.* 112:199–202.
65. Bedrossian, C. W. M., C. Kuhn, III, M. A. Luna, R. H. Conklin, R. B. Byrd, and P. D. Kaplan. 1977. Desquamative interstitial pneumonia-like reaction accompanying pulmonary lesions. *Chest* 72:166–169.
66. Sattler, F., L. Nichols, L. Hirano, A. Hiti, F. Hofman, C. Hughlett, L. Zeng, C. T. Boylen, and M. Koss. 1997. Nonspecific interstitial pneumonitis mimicking *Pneumocystis carinii* pneumonia. *Am. J. Respir. Crit. Care Med.* 156:912–917.